Small Incisions, Big Impact: Expanding Access to Minimally Invasive Cardiac Surgery at NICVD

Presenter:

Dr. Syeda Jabin Saria

Assistant Professor, Cardiac Surgery,
NICVD, Dhaka

Introduction

- “Smaller incision, lesser trauma, faster recovery”—this is the fundamental philosophy behind Minimally Invasive Cardiac Surgery (MICS)
- Over the past few decades, MICS has evolved from a technically demanding alternative to conventional median sternotomy into an increasingly established approach to cardiac surgery.
- It offers potential benefits including smaller incisions, reduced surgical trauma, less postoperative pain, fas recovery, shorter hospital stay, and improved cosme outcomes.

Introduction

- Despite these advantages, the adoption of MICS remains challenging, particularly in resource-constrained settings. Limited infrastructure, specialized equipment, training requirements, and appropriate patient selection can present significant barriers

- Nevertheless, innovation is not defined by resources alone—it is defined by how effectively we utilize ther

Introduction

- In this presentation, we present five diverse cases of minimally invasive cardiac surgery performed in a government-sector setting, highlighting our evolving experience, the variation in surgical approaches, patient selection, perioperative outcomes, and the challenges encountered along the way.
- Our experience demonstrates that, with appropriate patient selection, team expertise, and systematic development, minimally invasive cardiac surgery can successfully incorporated into a government cardiac surgery program.

CASE 1

Case Summary

- A 40-year-old male,
- Hailing from Dhaka, admitted in this hospital,
- As a diagnosed case of ASD secundum with mild TR
- Echocardiography findings:

  ASD secundum(30mm x 39mm)

  Mild TR

  Dilated RA & RV

  LVEF- 62%

  PASP- 42 mm of Hg

ন্যাশনাল হার্ট ফাউন্ডেশন হাসপাতাল অ্যান্ড রিসার্চ ইনস্টিটিউট
NATIONAL HEART FOUNDATION HOSPITAL & RESEARCH INSTITUTE

Description

2D & M-mode : Situs Solitus, Levocardia. Atrioventricular and ventriculoarterial concordance seen.
Great vessels are in normal relationship. Pulmonary venous drainage normal.
IAS: Echo dropout (30mm x 29mm, appeared fenestrated, lower echo dropout near IVC) seen in mid IAS.
IVS: Intact.
Chamber dimensions : Dilated RA & RV.
Paradoxic IVS. LV & RV systolic functions are good.
All valves are normal in morphology and in motion.
No PDA or coarctation seen.
No intracardiac mass seen. Normal pericardium. No effusion seen.

Colour Flow : ASD flow, L-R shunt. Mild TR (PASP: 42mmHg).

Comments :

- Secundum ASD (7 Fenestrated, lower echo dropout near IVC), L-R shunt.
- Mild TR (PASP: 42mmHg).
- Paradoxic IVS with good LV systolic function.
- Dilated RA & RV with good RV systolic function.
- Note: TEE was performed at NICVD, ASD was found not suitable for device closure.

Prof. Tahin Haque
MBBS, Ph D (Cardiac Imaging)
Professor, Echocardiography

Prepared By : Rakib

PLOT NO-7/2, SECTION-2, MIRPUR, DHAKA-1216, BANGLADESH
Phone : +88-02-58054768-12, Fax: +88-02-48039237, Facebook: www.facebook.com/bangladesh.heartfoundation
E-mail : nhfadmin@sgni.com, admin@nhf.org.bd

CARDIOVASCULAR SURGICAL CONFERENCE OF NICVD-2025

Case Summary

- After optimization, we planned for –

MICS Closure of ASD secundum under G/A with CPB

OT Note:

- **Date & time:** 28.04.26 ; from 11.00 am to 02.00 pm
- **Indication:** ASD secundum
- **N/O operation:** MICS ASD closure with GTPP
- **Incision:** Right antero-lateral

Thoracotomy(4th ICS) & Right groin

- **Anaesthesia:** under G/A with CPB
- **Pacing:** RV epicardium & Skin
- **Drain:** Right pleural cavity
- **XCT:** 71 mins
- **ECCT:** 150 mins



Outcome

- Patient tolerated the procedure well
- Patient post operative period was uneventful
- Patient was discharged home on 8th post operative day

CASE 2

Case Summary

- A 30-year-old female,
- Hailing from Chandpur, admitted in this hospital,
- As a diagnosed case of LA myxoma
- Echocardiography findings:

LA myxoma(25mm x 27mm)

Mild to Moderate Mitral valve inflow obstruction due to myxoma

Mildly dilated LA

LVEF- 62%

PASP- 32 mm of Hg

The Kabir Echo

[illegible]
Mobile : 01764 173 242, 01937 935 693

Color Doppler Echo Report

NAME :	Aktima	DATE :	May 17, 2026
ID :	3861/26	SEX :	Female
Ref. By :	Dr. Md. Mehedi Hasan	AGE :	30Years

MEASUREMENTS 2D :

AO	18 mm	LV-IDd	37 mm	RVIDd	27 mm	AoV annulus	mm
LA	26x40x41mm	LV-IDs	25 mm	MPA	19 mm	MV annulus (4C)	26 mm
IVST	09 mm	LV-FS	32 %	LPA	mm	MV annulus (2C)	mm
PWT	09 mm	LV-EF	62 %	RPA	mm	TV annulus	mm

DOPPLER MEASUREMENTS :

Parameters	Velocities	Peak Gradients	Mean Gradients	Others	
Mitral Valve	1.5 m/s	9.4 mm Hg	4.0 mm Hg	at HR = 96b/m	
Aortic Valve	1.2 m/s	5.7 mm Hg	mm Hg		
Tricuspid Valve	0.73 m/s	2.1 mm Hg	mm Hg		
Pulmonary Valve	1.0 m/s	3.9 mm Hg	mm Hg		
PASP = 32mmHg					

Chambers :

LA : Mildly dilated.
A large myxoma (size = 25mm x 27mm) found inside LA cavity.
The myxomatous mass, shows to-and-fro movement inside the cavity & protrude into mitral valve annulus during diastole causing mild-moderate inflow obstruction with MPG = 4.8mmHg.
The mass is attached by a short stalk at the lower part of IAS.

LV : No regional wall motion abnormality at rest. Good LV systolic function.

RA : Cavity within normal limit.

RV : Cavity within normal limit with good RV systolic function. TAPSE = 20mm

MV : Morphologically normal, functioning normally but there is mild-moderate mitral inflow obstruction by protruded LA myxoma during diastole (as described above).

AV : Three cusps, functioning normally.

PV : Normal. MPA and branch PAs are confluent and are normal sizes

TV : Morphologically normal with trivial TR. No TS.

IAS : Intact. IVS : Intact.

Left sided Aortic arch. No PDA. No coarctation of the aorta.

Pericardium : No pericardial effusion seen

IMPRESSION :
1) Left Atrial Myxoma (as described above).
2) Mild-moderate mitral valve inflow obstruction due to Myxoma.
3) Mildly dilated LA
4) Good LV & RV systolic function. LVEF= 62%.
5) PASP = 32mmHg.

Option : Excision of LA myxoma
Note : Previous echo report reviewed at the time of present echo study
Please correlate with other parameters.

Prof. Dr. Md. Kabiruzzaman
MBBS, MD (Cardiology) FNIC (India)
Fellowship in Clinical Cardiology & Echocardiography
Adult, child / congenital Echo and vascular Doppler
Cardiologist & Medicine Specialist
Course Director, Bangladesh Academy of Echocardiography

CARDIOVASCULAR SURGICAL CONFERENCE OF NICVD-2026

Case Summary

- After optimization, we planned for –

MICS excision of LA myxoma under G/A with CPB

OT Note:

- **Date & time:** 07.06.26 ; from 08.00 am to 01.00 pm
- **Indication:** LA myxoma
- **N/O operation:** MICS excision of LA myxoma
- **Incision:** Right antero-lateral

Thoracotomy(4th ICS) & Right groin

- **Anaesthesia:** under G/A with CPB
- **Pacing:** RV epicardium & Skin
- **Drain:** Right pleural cavity
- **XCT: 57** mins
- **ECCT: 97** mins



MICS LA myxoma excision Procedure

Resected specimen of LA myxoma



Outcome

- Patient tolerated the procedure well
- Patient post operative period was uneventful
- Patient was discharged home on 7th post operative day

CASE 3

Case Summary

- A 38-year-old male,
- Hailing from Shariatpur, admitted in this hospital,
- As a diagnosed case of CRHD with MS(severe) with LA thrombus with pulmonary HTN(moderate)
- Echocardiography findings:

  CRHD with MS(severe, MVA 0.8 cm square)

  Mild AR with TR

  Left atrial thrombuds

  LVEF- 53%

  PASP- 50 mm of Hg

পপুলার ডায়াগনস্টিক সেন্টার লিঃ
POPULAR DIAGNOSTIC CENTRE LTD.
POPULAR
Shyamoli Branch Unit-2 : House - 5/1, Block - B, College Gate, Opposite Shaheed Suhrawardy Hospital
Mohammadpur, Dhaka, Hotline : 09666787806
Head Office : House # 16, Road # 2, Dhanmondi, Dhaka, Hotline : 13631, 09666787801, E-mail : info@populardiagnostic.com, Web : www.populardiagnostic.com

Patient Name	SAIFUL ISLAM	RIS No	112721226
UHID	SHM660386	Registration Date	
Age/Gender	38 Y / M	Report Date	28/02/2026
Referred By	Prof. Dr. A.K.M. Monwarul Islam, MBBS(DMC), FCPS(Medicine), MD(Cardiology), FACP, FACC, FASE, FESC, FESC, FRCP(Edin).		
Investigation	Echo Colour Doppler		

Echo window is fair.

AD	33 mm	LVIDD	36 mm	RVID	mm	AV Annulus		20 mm
LA	59 mm	LVIDS	41 mm	PA	mm	MV Annulus (PLX)		32 mm
IVST	06 mm	FS	28 %	LPA	mm	MV Annulus (4")		32 mm
PWT	06 mm	EF	53 %	RPA	mm	ACS		11 mm

Doppler Measurements:

Parameters	Velocity	Peak Gradients	Mean Gradients	Others
Mitral valve	2.20 m/s	19.41 mm Hg	12.17 mm Hg	MVA (PHT) cm²
Aortic valve	2.02 m/s	16.21 mm Hg	11.20 mm Hg	E/A Ratio
Tricuspid Valve	0.72 m/s	2.06 mm Hg	mm Hg	DT ms
Pulmonary Valve	0.90 m/s	3.27 mm Hg	mm Hg	E/E
Pulmonary Arterial Pressure		PASP 50 mm Hg	PADP mm Hg	PER

Chambers:

LA : Dilated. Spontaneous echo contrast in LA. Thrombus in LA appendage.
LV : Cavity dimensions are within normal limits. Systolic function is fair.
RA : Cavity dimensions are within normal limits.
RV : Cavity dimensions and wall motions are within normal limits. TAPSE 17 mm.

Valves:

MV : Both AML and PML are thickened and mildly calcified. Commissures are fused, mobility of AML is restricted. PML is virtually immobile. MVA is 0.8 cm² by planimetry. Mitral annulus is mildly calcified. There are moderate subvalvular changes.
PV : Normal
AV : Tricuspid, cusps are thickened and mildly calcified, mobility is mildly restricted with mild systolic doming. Aortic root and ascending aorta is mildly calcified and is of normal caliber. Aortic annulus 20 mm, aortic sinus 32 mm, sino-tubular junction 27 mm and ascending aorta 32 mm.
TV : Leaflets are thickened, mobility is good.

IAS : Intact. IVS : Intact.

Pericardium: No pericardial effusion. Thrombus/ Vegetation/ Other Mass: Described above.
IVC: Normal in caliber (18 mm), collapsibility is <50%. Estimated RA pressure is 08 mmHg.
Doppler study: Trivial MR, mild grade I AR and mild TR flows are seen.

IMPRESSION:
Chronic rheumatic heart disease
Mitral stenosis (Severe, MVA 0.8 cm²)
Aortic stenosis (Mild, AV MPG 11 mmHg)
Aortic regurgitation (Mild, grade I)
Tricuspid regurgitation (Mild), PASP 50 mmHg
Fair LV systolic function (LVEF 53%)
Good RV systolic function
Left atrial thrombus.

Note: During echo evaluation: AF, ventricular rate 82/min, BP 92/66 mmHg.
Advice: Medical management followed by MVR + LA volume reduction.

Dr. A.K.M. Monwarul Islam
MBBS (DMC), FCPS (Med), MD (Card)
FRCP (Edin), FACP, FACC, FESC, FASE, FAHA
Consultant cardiologist and Internist
Popular Diagnostic Center Ltd, Dhaka

Prepared By: Nasser

CARDIOVASCULAR SURGICAL CONFERENCE OF NICVD-2026

Case Summary

- After optimization, we planned for –

MICS Mitral valve replacement (MVR) under G/A with CPB

OT Note:

- **Date & time:** 09.08.26 ; from 08.30 pm 02.00 pm
- **Indication:** ASD secundum
- **N/O operation:** MICS MVR with 31 mm St. Judes BLMV

Thoracotomy(4th ICS) & Right groin

- **Anaesthesia:** under G/A with CPB
- **Pacing:** RV epicardium & Skin
- **Drain:** Right pleural cavity
- **XCT:** 82 mins
- **ECCT:** 135 mins

Outcome

- Patient tolerated the procedure well
- Patient post operative period was uneventful
- Patient was discharged home on 8th post operative day

CASE 4



Case Summary

- A 15-year-old female,
- Hailing from Natore, admitted in this hospital,
- As a diagnosed case of ASD secundum
- Echocardiography findings:

  ASD secundum (14 mm x 17mm)

  Dilated RA & RV

  LVEF- 62%

  PASP- 35 mm of Hg

The Kabir Echo

চেম্বার :
ইসলামপুর মৃধা এন্ড জেনারেল হাসপাতাল (২য় তলা)।
৯ ইসলামপুর (১ম তলা, সিরাজগঞ্জ) মেডিকেল হলের (দক্ষিণ পাশে)। ফোনালাপের সময়সীমা সকাল ৯টা থেকে বিকাল ৫টা পর্যন্ত।
বাসস্ট্যান্ড মুক্তিরহাট ট্রাক মোড় হতে ৫০ গজ পশ্চিম দিকে।
"আলোকপাত স্মৃতি এক অনুসন্ধিৎসু হাসপাতালের" সহযোগিতায়।
Mobile : 01794 173 242, 01937 935 893

Color Doppler Echo Report

NAME :	Jim Khatun	DATE:	July 13, 2026
ID :	8426	SEX:	Female
Ref. By:	NICVD	AGE:	16 Years

MEASUREMENTS 2D :

AO	mm	LV-IDd	39 mm	RVIDd	47 mm	AoV annulus	17 mm
LA	27 mm	LV-IDs	24 mm	RVOT	mm	MV Annulus	26 mm
IVST	08 mm	LV-FS	33 %	MPA	33 mm	TV annulus	40 mm
PWT	08 mm	LV-EF	62 %		mm	PV annulus	28 mm

DOPPLER MEASUREMENTS:

Parameters	Velocities	Peak Gradients	Mean Gradients	Others	
Mitral Valve	1.0 m/s	4.4 mm Hg	mm Hg		
Aortic Valve	0.71 m/s	2.0 mm Hg	mm Hg		
Tricuspid Valve	1.1 m/s	5.6 mm Hg	mm Hg		
Pulmonary Valve	1.1 m/s	5.4 mm Hg	mm Hg		
PASP= 35mmHg					

DESCRIPTION : Situs Solitus, Levocardia, two atria, two ventricles, two AV valves, atrioventricular and Ventriculoarterial concordance with normally related great arteries.
Normal systemic & pulmonary venous drainage.

Chambers :

LA : Cavity within normal limit. Appendage, clear.
LV : Cavity within normal limit, no regional wall motion abnormality at rest with good LV systolic function.
RA : Dilated.
RV : Dilated with features of volume overload & good RV systolic function.
RVOT : No RVOT obstruction.

Valves:

MV : Both leaflets are mildly thickened, looks myxomatous, shows good diastolic opening but prolapse of coapting part of AML during systole causing mild-moderate MR (Jet area = 3.6 cm²). Eccentric MR jet. No MS.
AoV : Three cusps, functioning normally.
PV : Functioning normally.
MPA and branch PAs are confluent and are dilated.
TV : Annulus is dilated with trivial TR. No TS.
IAS : There is aneurysm of IAS & multiple fenestrated defects involving the aneurysm part of secundum septum (accumulated size = 14mm x 17mm), large with Lt-Rt shunt.
Note: There are adequate rims of IAS.
IVS : Intact
Left sided aortic arch. No PDA. No coarctation. No PLSVC.

Pericardium : No pericardial effusion.

IMPRESSION:
1) Situs Solitus, Levocardia.
2) ASD secundum, large, fenestrated & aneurysm of IAS (as described above).
3) MVP with mild-moderate MR
4) Dilated RA & RV with features of volume overload.
5) No regional wall motion abnormality at rest.
6) Good LV & RV systolic function. LVEF= 62%.
7) PASP = 35mmHg.

Option: Surgical repair.
Note: Previous echo report reviewed at the time of present echo study.
Please correlate with other paramaters.

Prepared by: Mitu

Prof. Dr. Md. Kabiruzzaman
MBBS, MD (Cardiology), FNIC (India)
Fellowship in Ch. Cardiology & Echocardiography
Adult, Child / Congenital Echo
Cardiologist & Medicine Specialist
Course Director,
Bangladesh Academy of Echocardiography

CARDIOVASCULAR SURGICAL CONFERENCE OF NICVD-2026

Color Doppler Echo, 2D-Echo এর মাধ্যমে হৃদরোগ সংক্রান্ত ভালোভাবে Color Doppler Echo a Cardiac Disease

Case Summary

- After optimization, we planned for –

MICS Closure of ASD secundum under G/A with CPB

OT Note:

- **Date & time:** 23.08.26 ; from 12.10 pm 04.40 pm
- **Indication:** ASD secundum
- **N/O operation:** MICS ASD closure with GTPP
- **Incision:** Right antero-lateral

Thoracotomy(4th ICS) & Right groin

- **Anaesthesia:** under G/A with CPB
- **Pacing:** RV epicardium & Skin
- **Drain:** Right pleural cavity
- **XCT:** 51 mins
- **ECCT:** 110 mins

Outcome

- Patient tolerated the procedure well
- Patient post operative period was uneventful
- Patient was discharged home on 8th post operative day

CASE 5



Case Summary

- A 32-year-old female,
- Hailing from Tangail, admitted in this hospital,
- As a diagnosed case of ASD secundum
- Echocardiography findings:

  ASD secundum (18 mm x 27mm)

  Dilated RA & RV

  LVEF- 62%

  PASP- 41 mm of Hg

The Kabir Echo

চেম্বার :
বাংলাদেশ হার্ট এন্ড এলাম ক্লিনিক ফাউন্ডেশন (বাফা) :
৯ কাজলাপুর (চর্ম ভবন, কিলোমিটার-৩) মহিলা কলেজ (পশ্চিম পাশে) : কাজলাপুর বাসস্ট্যান্ড :
হাসপাতাল মুখী বাসের ট্রিপ থেকে ৫০ গজ পশ্চিম দিকে :
"বাংলাদেশ সোসাইটি অব কার্ডিওভাস্কুলার হাসপাতালস" পাশের বিল্ডিং :
Mobile : 01754 173 242, 01937 935 893

Color Doppler Echo Report

NAME :	Amena Begum	DATE:	August 25, 2026
ID :	6765/25	SEX :	Female
Ref. By :	Assoc. Prof. Dr. Mohammad Fazle Maruf, MBBS, MS (CV & TS), FACS.	AGE :	32Yrs

MEASUREMENTS 2D :

AO		mm	LV-IDd	34	mm	RVIDd	45	mm	AoV annulus	15	mm
LA	20	mm	LV-IDs	23	mm	MPA	32	mm	MV annulus	24	mm
IVST	09	mm	LV-FS	32	%	LPA		mm	TV annulus	29	mm
PWT	09	mm	LV-EF	62	%	RPA		mm	PV annulus	22	mm

DOPPLER MEASUREMENTS :

Parameters	Velocities	Peak Gradients	Mean Gradients	Others	
Mitral Valve	0.93 m/s	3.4 mm Hg	mm Hg		
Aortic Valve	0.83 m/s	2.9 mm Hg	mm Hg		
Tricuspid Valve	1.0 m/s	4.4 mm Hg	mm Hg		
Pulmonary Valve	1.7 m/s	12.5 mm Hg	mm Hg		
PASP = 41mmHg					

DESCRIPTION :

Chambers : Situs Solitus, Levocardia, two atria, two ventricles, two AV valves, atrioventricular and Ventriculoarterial concordance with normally related great arteries. Normal systemic & pulmonary venous drainage.

LA : Cavity within normal limit. Appendage : clear.
LV : Cavity within normal limit.
No regional wall motion abnormality at rest. Good LV systolic function.

RA : Dilated.
RV : Dilated with features of volume overload with good RV systolic function.
RVOT : No RVOT obstruction.
Valves :
MV : Morphologically normal, functioning normally. No MVP.
AoV : Three cusps, functioning normally.

PV : Normal. No PR. No PS. MPA and branch PAs are confluent and are dilated.
TV : Annulus is dilated with mild TR. No TS.

IAS : There is a defect involving the secundum part (size = 18mm x 27mm), large with Lt-Rt shunt.
Note : Retro-aortic, mitral & IVC rims are short.
IVS : Intact.

Left sided aortic arch. No PDA. No coarctation of the aorta.

Pericardium : No pericardial effusion.

IMPRESSION:
1) Situs Solitus, Levocardia.
2) ASD secundum, large (as described above).
3) Dilated RA & RV with features of volume overload.
4) Good LV & RV systolic function. LVEF= 62%.
5) PASP = 41mmHg.

Option : ASD closure : Surgery / ? Device
Note : Please correlate with other parameters.

Prof. Dr. Md. Kabiruzzaman
MBBS, MD, (Cardiology) FNIC (India)
Fellowship in Cli Cardiology & Echocardiography
Adult child / congenital Echo and vascular Doppler

CARDIOVASCULAR SURGICAL CONFERENCE OF NICVD-2026

Case Summary

- After optimization, we planned for –

MICS Closure of ASD secundum under G/A with CPB

OT Note:

- **Date & time:** 13.09.26 ; from 09.10 am 01.00 pm
- **Indication:** ASD secundum
- **N/O operation:** MICS ASD direct closure
- **Incision:** Right antero-lateral

Thoracotomy(4th ICS) & Right groin incision

- **Anaesthesia:** under G/A with CPB
- **Pacing:** RV epicardium & Skin
- **Drain:** Right pleural cavity
- **XCT:** 41 mins
- **ECCT:** 66 mins



MICS ASD Direct Closure Procedure



Skin painting & Draping





Rt. Groin incision and exposure 0f CFA & Vein





Rt. Antero-lateral thoracotomy with pericardiotomy



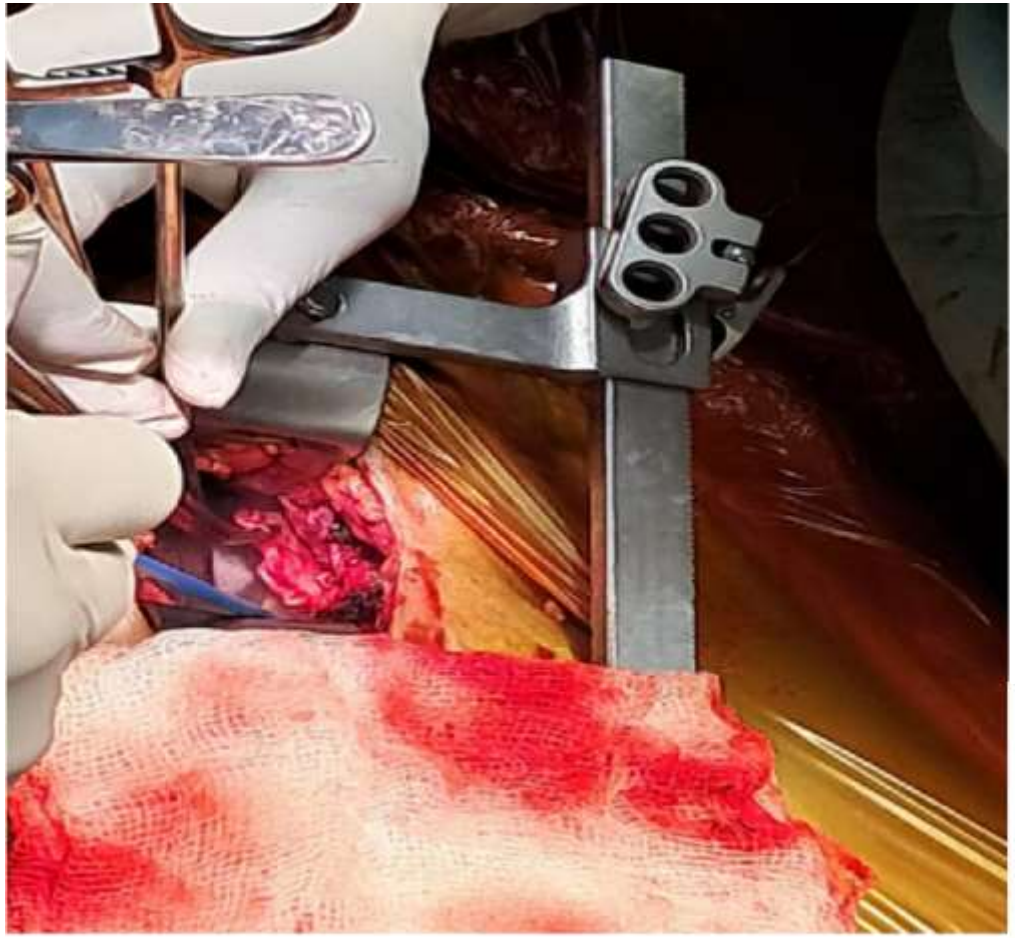

Per Operative TEE showing ASD secundum

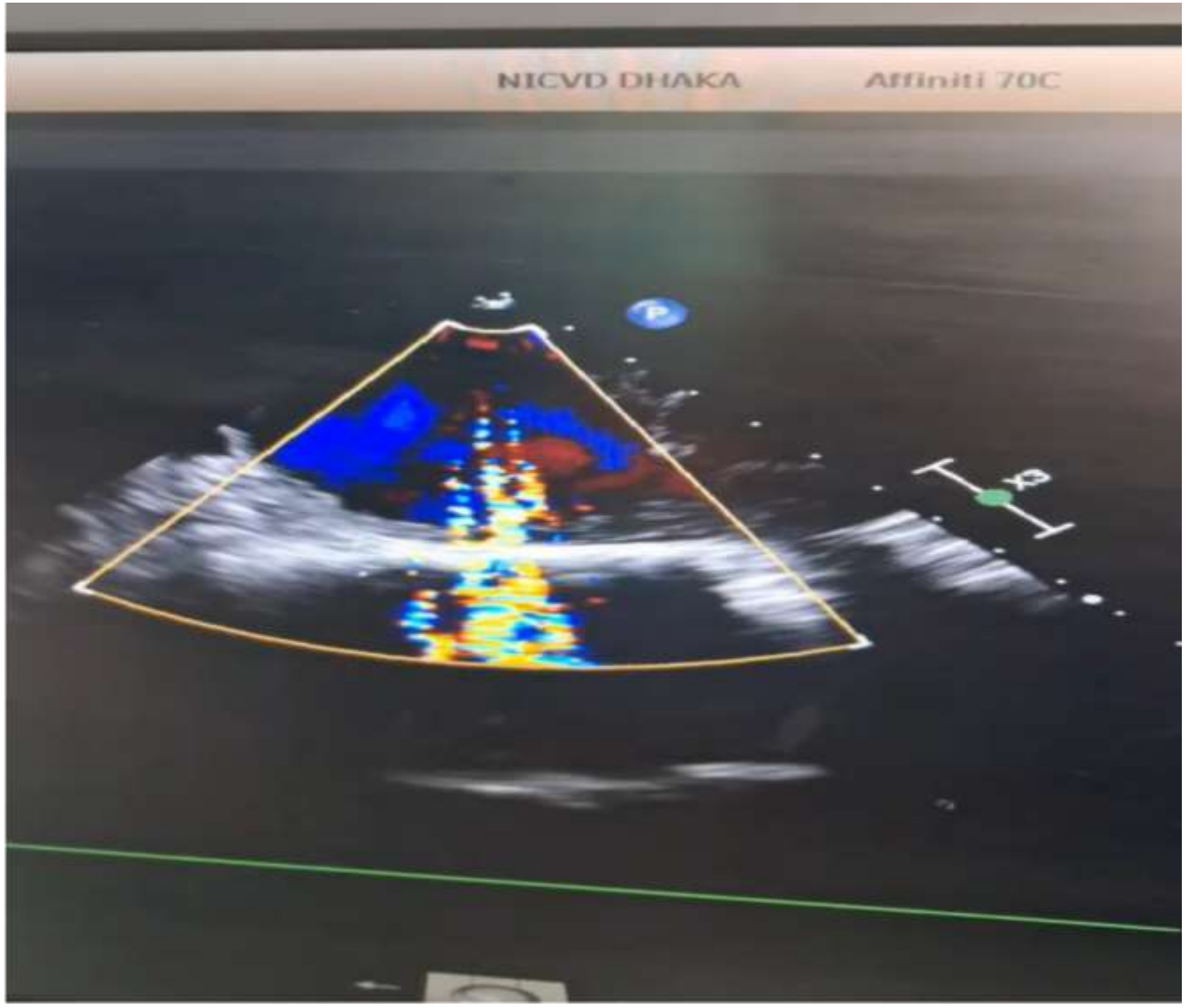

Peripheral & aortic cannulation and CPB establishment procedure



Steps of procedure:

- Incision on groin crease over the femoral pulsation
- Exposure of femoral artery & the vein
- Louping of femoral artery proximally & distally
- Purseting over femoral vein
- Introduction of 16Fr cannula on femoral artery
- Introduce guide wire
- Gradual dilatation with the dilators
- Introduction of arterial cannula, connect with arterial line & fixation.
- Venous cannulation in same technique with the guidance of TEE
- Root cannulation for CP on ascending aorta
- Application of cross clamp



Peripheral cannulation

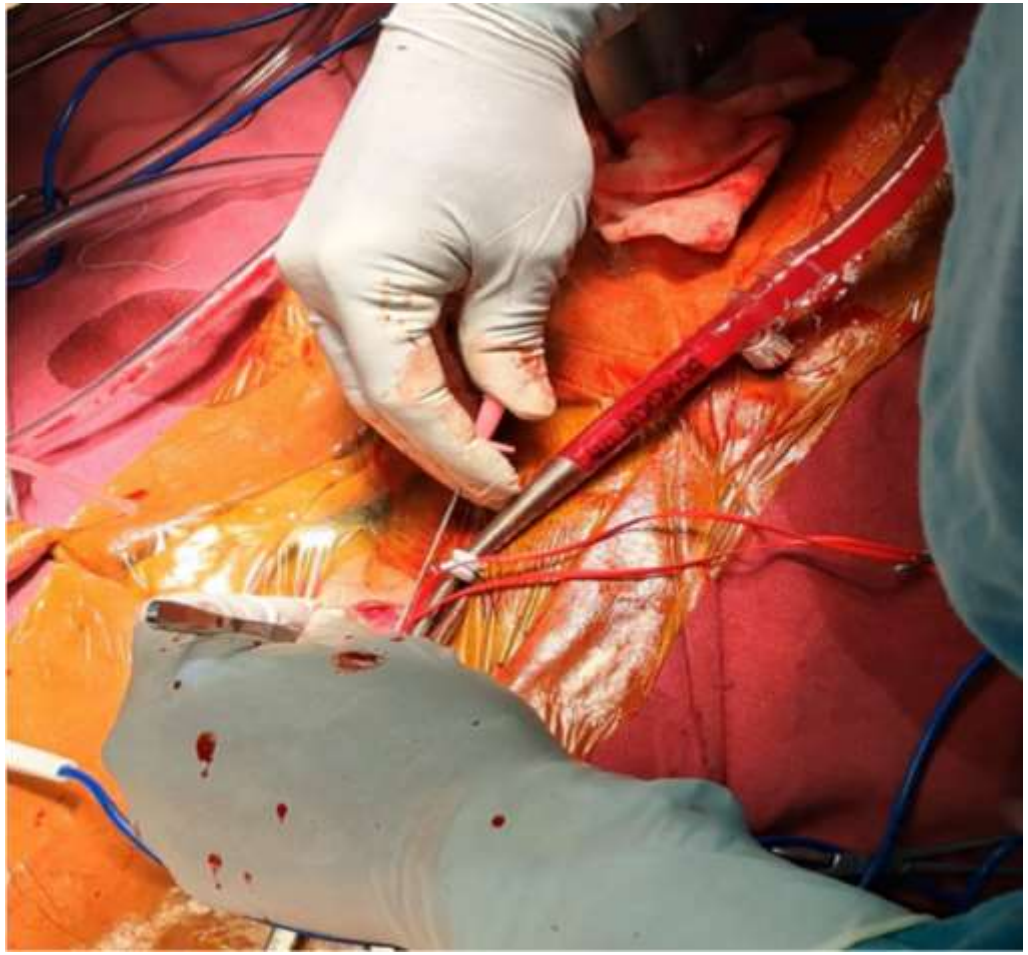

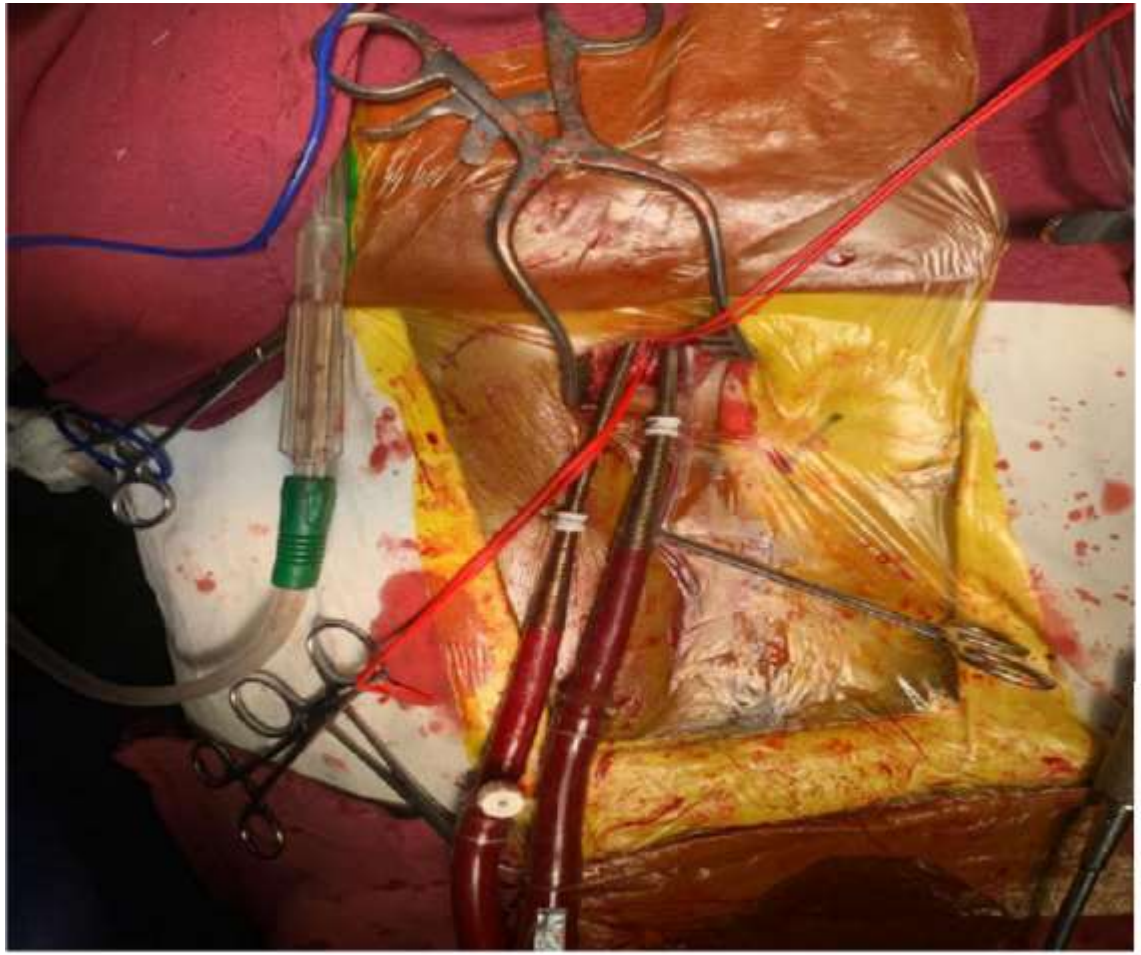

Aortic root cannulation

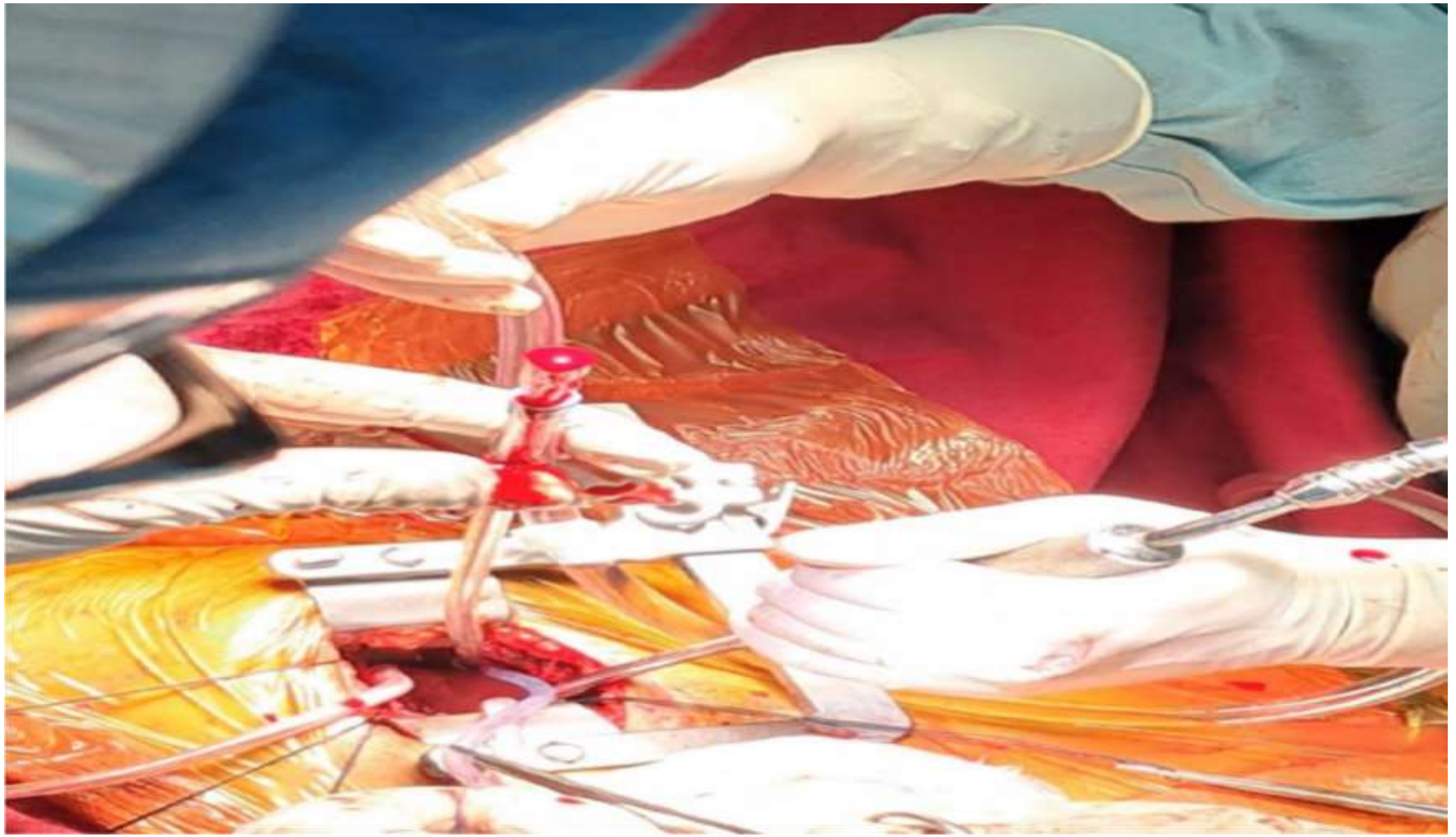

Aortic cross clamp application



Cardioplegia establishment



RA-tomy done & stay suture taken

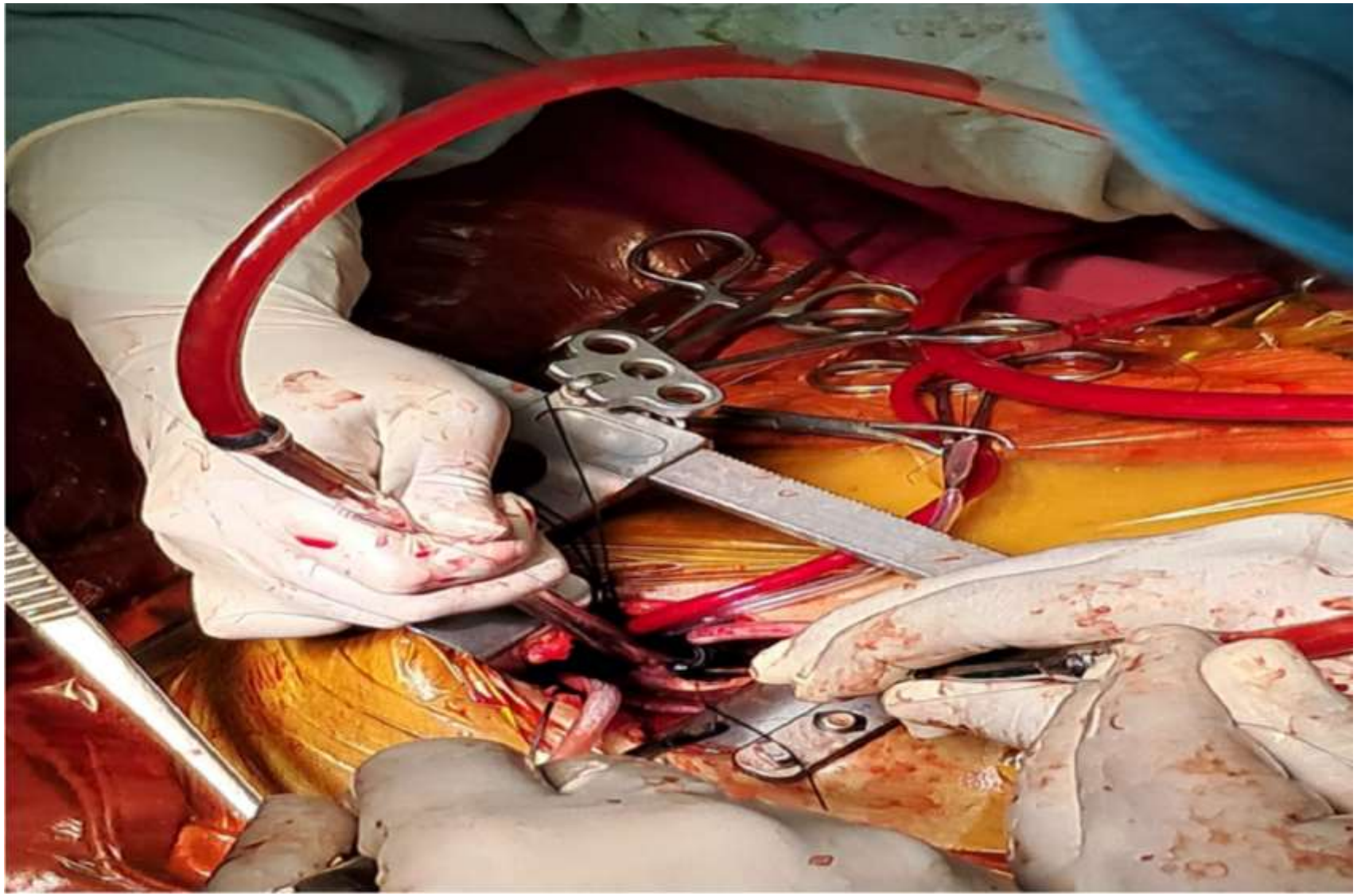

ASD direct closure done

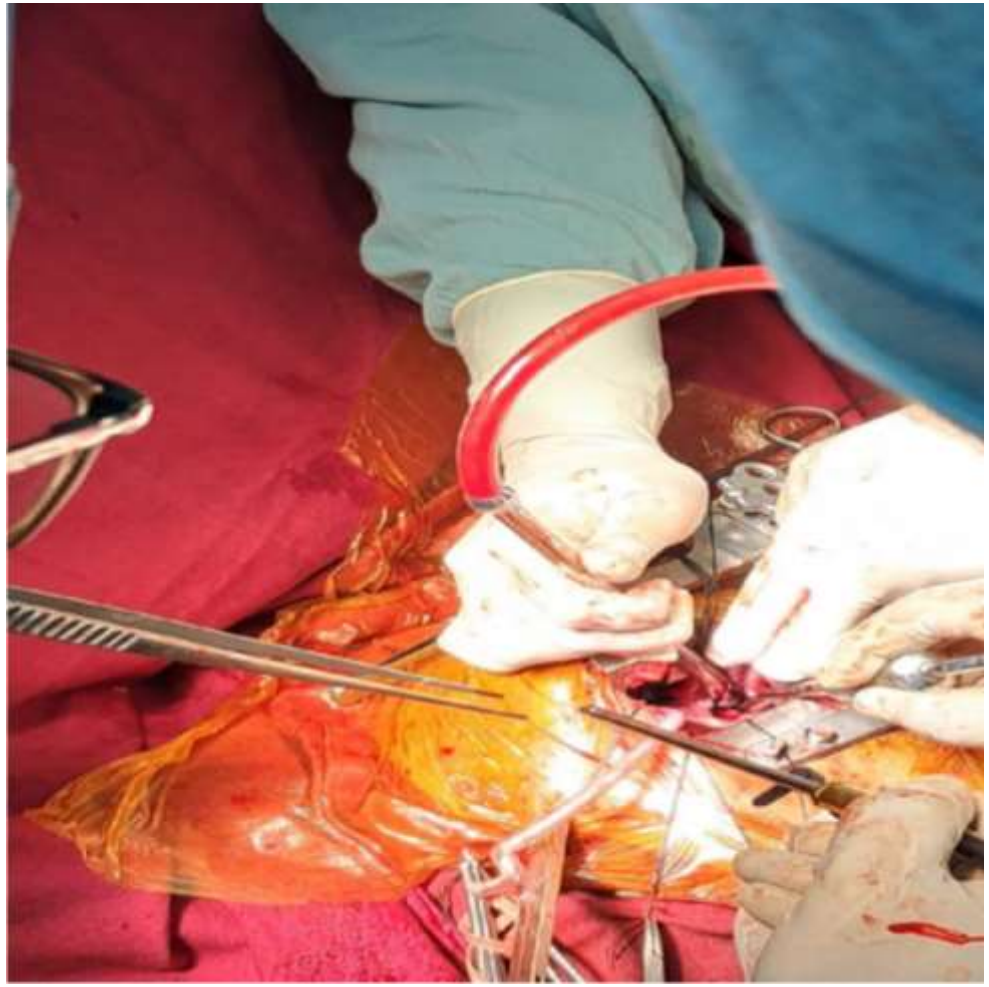

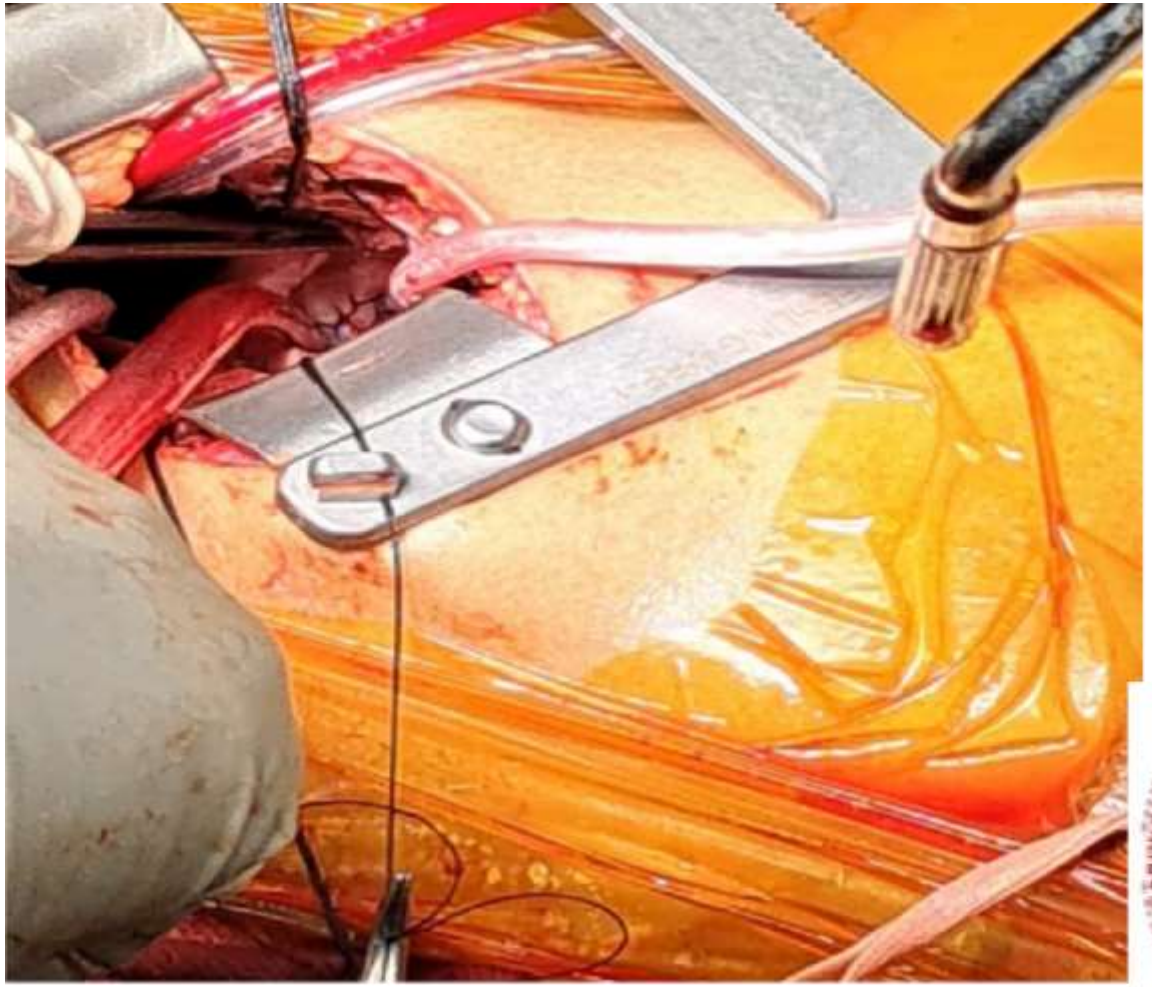

RA-tomy closed



De-cannulations & repair:

After proper deaeration aortic cross clamp is released.

With communicating Perfusionist & Anaesthesiologist decannulation of root cannula & venous cannula with tightening purseting. Arterial decannulation site is repaired by 6/0 proline

After secure bleeding & confirming distal pulsation closure done in layers.

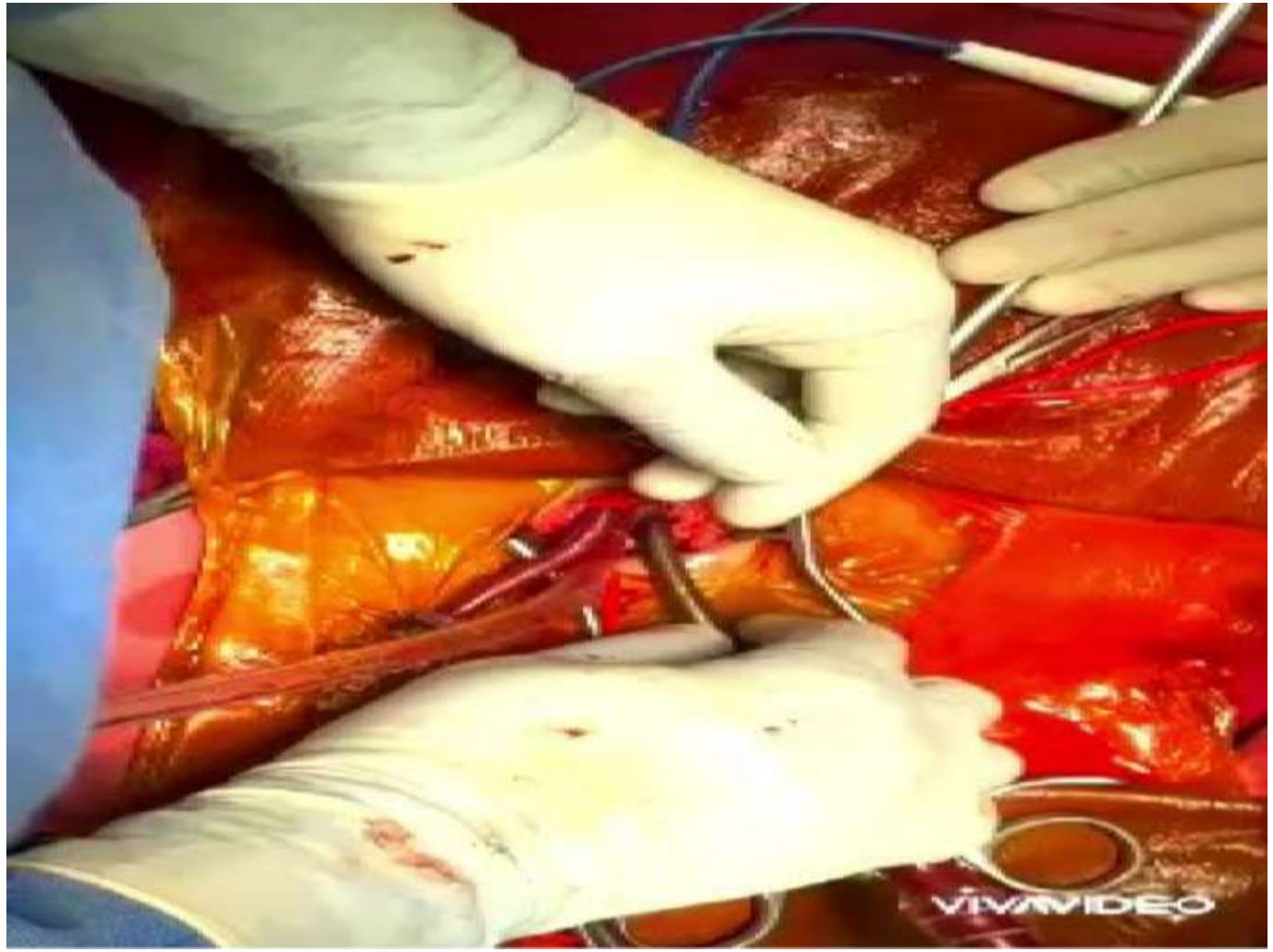

CLOSING OF CHEST STEP BY STEP

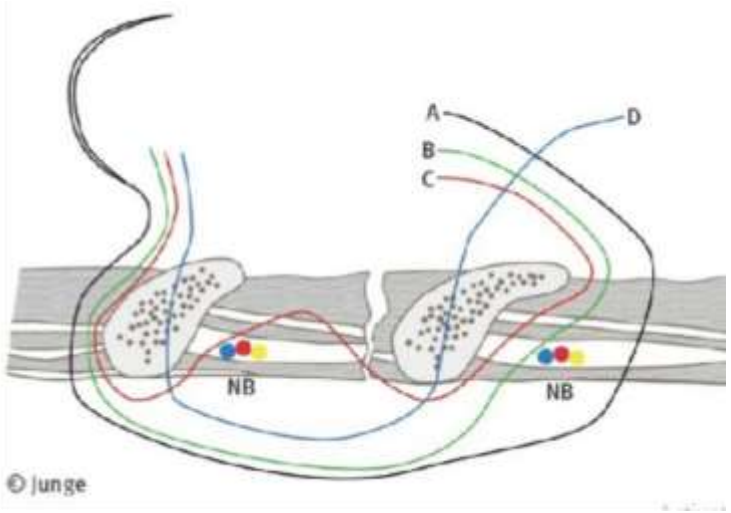













After Closing

Chest wound



Groin wound

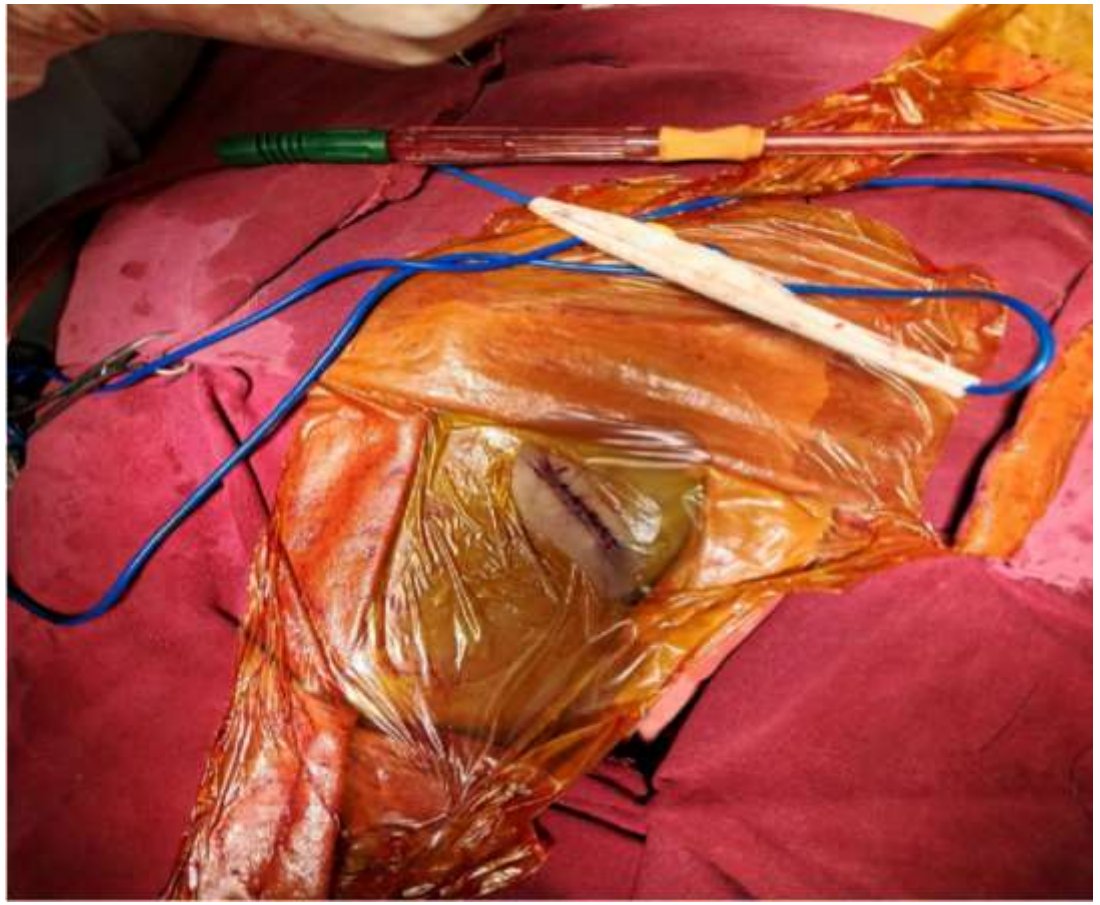

Outcome

- Patient tolerated the procedure well
- Patient post operative period was uneventful

Team CSU- **Green**



Conclusion

We barely could continue the journey of MICS to survive but our mission is to expand this horizon and transform it from innovation to standardized regular practice and beyond.

Thank YOU

Questions & Discussion- Welcome